

Case: Balloon Angioplasty of the Tibioperoneal truncus

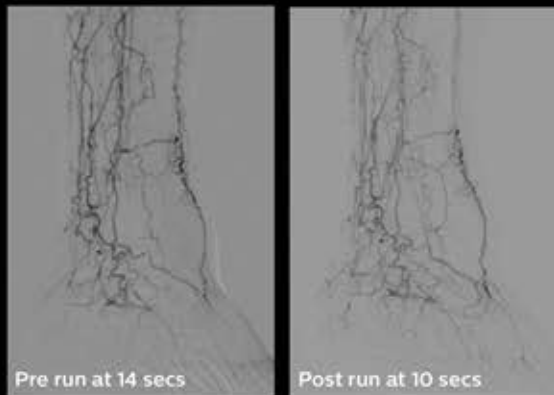
Patient:

- 92 year old male
- Diabetes
- Non healing ulcer dig2

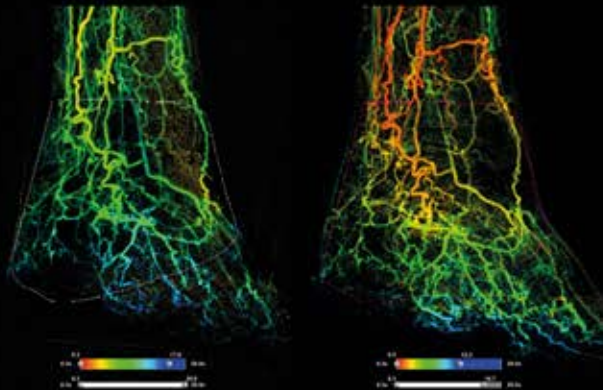
Treatment:

- Balloon angioplasty of the Tibioperoneal truncus (3 mm balloon)

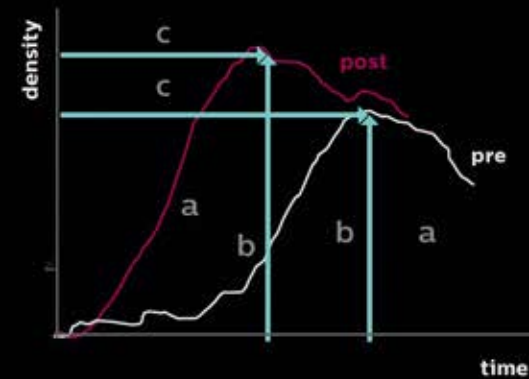
A usability study showed **92%** of the users believe SmartPerfusion supports them in defining the endpoint of the treatment⁷



No significant differences between pre and post DSA runs other than slightly faster inflow on post



The color coded image also shows faster inflow in the post run



Significant increase in contrast passage, as demonstrated by:

- larger Area under Curve (a)
- higher Peak density (b)
- shorter time to peak (c)

Considering the different parameters, the overall perfusion in the foot has increased, which is not clear based on the pre and post DSA's