



Combining modalities for more confident diagnoses

Philips EPIQ 7 ultrasound for image fusion and CEUS

Who/where

Dr. Dirk-André Clevert, Associate Professor of Radiology, is the Section Chief of the Interdisciplinary Ultrasound Center at Munich University Hospital Grosshadern, which is part of one of the largest medical complexes in Germany. Dr. Clevert uses the fully integrated fusion capabilities of the Philips EPIQ 7 ultrasound system for advanced visualization, combining the strengths of multiple imaging modalities to enhance diagnostic confidence.

Challenge

CT and MRI exams do not always provide enough information for a confident diagnosis or to determine potential progression of lesions. In addition, these exams and the contrast agents used with them can be expensive. CT and MR contrast agents are also potentially nephrotoxic, which can be of concern in an older patient population. Ultrasound imaging has not always afforded the necessary penetration and frame rate required for highly effective contrast imaging.

Solution

The Philips EPIQ 7 ultrasound system, which features the most powerful Philips architecture ever applied to ultrasound imaging, provides fast and efficient multimodality image fusion for the effective characterization of lesions that may be unclear on a CT or MR exam. Fusing existing CT or MR images with live ultrasound and the use of CEUS can aid in the characterization of lesions, enhancing diagnostic confidence, reducing the number of follow-up CT or MR scans needed, and protecting the patient from unnecessary exposure to nephrotoxic contrast agents.

Bringing more clarity to lesion characterization

Since 2004 Dr. Dirk-André Clevert has headed the Interdisciplinary Ultrasound Center at the Munich University Clinic Grosshadern in Munich, Germany, and performs all interventional ultrasounds at the center, including contrast-enhanced ultrasound (CEUS). In a year, the center performs approximately 20,000 ultrasound exams across seven sites. Dr. Clevert performs CEUS for approximately 1,200 patients a year, usually to evaluate lesions in the kidney and liver, as well as vascular lesions. He performs three to five fusion exams a week and between 20 to 25 contrast exams without fusion. He relies mainly on the xMATRIX and abdominal transducers for fusion exams.

With EPIQ 7, contrast-enhanced ultrasound (CEUS) workflow is now seamlessly integrated into virtually any exam, and the high-order parallel processing provided by nSIGHT Imaging allows for higher 2D and 3D frame rates during contrast imaging so that no dynamic information is lost.

Adding value to existing images

Fully integrated fusion capabilities mean that Dr. Clevert can now use multimodality query retrieve to view DICOM images such as CT and MR, allowing him to easily

compare past and current studies without the use of an external reading station and even review these multimodality images while live imaging. This helps users such as Dr. Clevert to leverage the strength of existing CT or MR scans with real-time ultrasound to create an information-rich fused image, which can aid diagnostic confidence. Dr. Clevert explains, “What we can do from a clinical perspective is to characterize lesions and gain additional information not available by CT or MR alone.”

Meaningful clinical advances

Dr. Clevert values Philips innovations such as the xMATRIX transducer, which gives him the option of 4D volume scanning and also to perform CEUS 4D volume scanning. He comments that the Philips xPlane view aids in confirming diagnosis, saying, “The capability for two planes in real time is very helpful in ruling out pathology or to determine if a lesion has infiltrated or not infiltrated.” Performing a contrast exam is now even easier with EPIQ 7, says Dr. Clevert. “Going from conventional grayscale to contrast there’s no longer any need to adjust the images. It’s the same image as before with the same penetration depth. So really the complete workflow saves a lot of time and also improves our daily work. Compared to our previous iU22 system, it’s like night and day.”

Dr. Clevert continues, “You have a better quality of image due to the higher frequency. You have more information, which is not available with conventional abdominal imaging, to determine if it’s a lesion or an artifact. Due to advantages in the technique you can improve the penetration, and also the workflow is now much more intelligent.”

Another feature surprised Dr. Clevert about EPIQ. “When I first saw the system, I thought, ‘Something is wrong.’ Because I heard nothing. It was a total lack of noise, and now the air conditioner in the room makes much more noise compared to the system.”

Maximizing the usefulness of prior scans

“Any unclear lesion depicted on just CT or MR means that I could not confirm what kind of lesion it is, or if a second opinion is needed,” he continues. “When we use the EPIQ system to rule out the pathology we have either MR or CT side by side to ultrasound. So, for example, if you’re an expert at CT imaging you can see and evaluate the same lesion using the CT image, the ultrasound exam, and the behavior of the lesion in response to the contrast agent.”

“In our department we use EPIQ 7 for diagnostic confidence,” says Dr. Clevert. “For unclear lesions we rule out what kind of lesion it might be. Even when we perform high-end CT or MR scans there are cases in which the lesions are unclear. In addition, outpatient CT exams can sometimes be of poorer quality, at times due to patient movement or scanning limitations. We don’t repeat the CT or MR examination, instead we make use of the existing CT or MR image with additional fusion.”

Reducing radiation and exposure to contrast agents

Dr. Clevert also notes that with the use of EPIQ 7, exposure to radiation and to nephrotoxic CT and MR contrast agents can be reduced. “These agents could damage the kidney. If you think about the older generation, they have problems with the kidneys. If you can save these kinds of contrast, you could protect the kidneys,” he reasons.

Improving workflow and finding small lesions

The use of fusion imaging with EPIQ 7 has offered improvements in workflow while enhancing patient care. “Now my colleagues from the CT and MR departments see the advantage of this new technique,” says Dr. Clevert. “About 30% of my patients come from the CT or MR department with the recommendation for additional images for any unclear liver, kidney, or vascular case. It helps with more efficient scheduling because the CT department has already done the scanning, but has discovered that there is something that is unclear.”



*Dirk-André Clevert, MD
Associate Professor of Radiology
Section Chief
Interdisciplinary Ultrasound Center at
Munich University Hospital Grosshadern
Munich, Germany*

“Having those scans saves us time in finding the lesion.” He elaborates, “Sometimes the lesions are tiny – as small as 1 cm. It can also be challenging to find lesions on the liver with the same certainty as on tissue. But if we know in advance where the lesion is on the kidney or the liver or if it’s diffuse, then we can mark both sides and find it much easier. We use the CT or MR data for detection and then we do characterization with the fused image.”

“With this new tool, we now have a bridge between the modalities...it combines the advantages of a CT or MR examination with the additional certainty of live ultrasound.”

Dirk-André Clevert, MD

Bridging the modalities

Gaining more complete information to guide treatment

By combining imaging modalities directly on the ultrasound system, Dr. Clevert now has access to an even more powerful diagnostic tool with advanced visualization, allowing for fast decisions compared to without fusion. “Philips has combined fusion and ultrasound strengths in one system and we have access to all images and all data, which is better for diagnostic purposes,” he notes.

“We can now determine that what we find on a scan is a lesion, but not cancer. We can also find recurrence, which would not be clear on either CT or MR alone. You can use a prior CT or MR examination as a baseline, so if the patient has had three liver metastases in the past, and you perform an MR and now find a fourth lesion, you can say with greater confidence if it’s a progression or if the previous MR or CT exam missed something. You can measure and compare it side by side.”

He elaborates, “If you make a sweep through the liver and find a lesion with a diameter of about 3 cm in the first CT or MR examination, now you can measure and compare it. If it’s still 3 cm, it seems to me at the moment of examination to be a stable disease that has not progressed. It’s very important as it applies to treatment. Now we can monitor the success of this therapy without as many MR or CT exams. This does not mean that you should stop every CT or MR examination but perhaps you’re able to conduct them at longer intervals by taking the previous data from CT or MR and using fusion to determine whether or not the disease has progressed,” he summarizes.

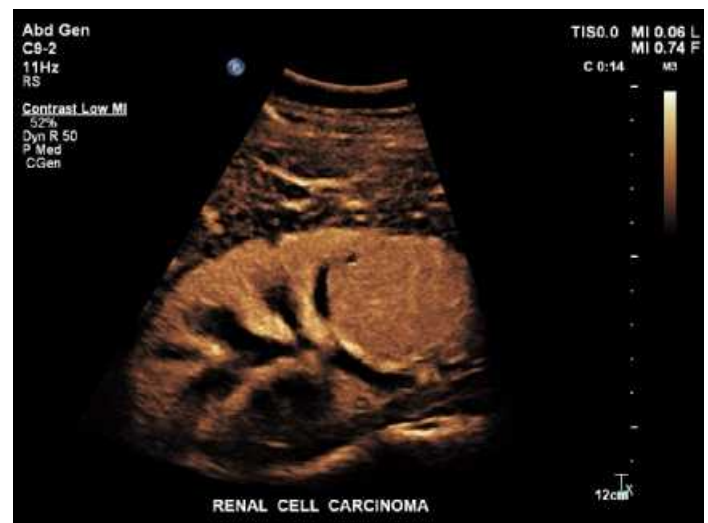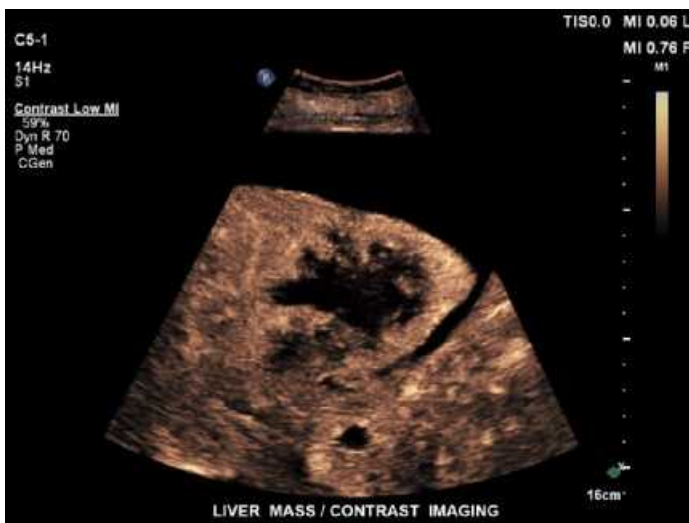Bringing the strengths of CT to ultrasound

“Sometimes we have very complex lesions, which are not really clear on ultrasound alone. So I can use the advantages of CT, which provides some information that is not available with ultrasound, and combine

the strengths of ultrasound with the strengths of CT. And if you think about both advantages and combine them, it gives you a greater advantage than looking at only one modality,” he affirms.

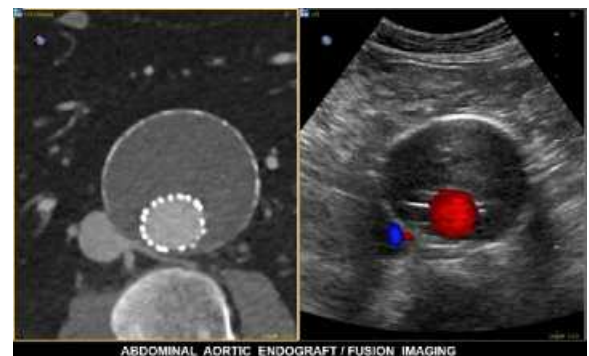
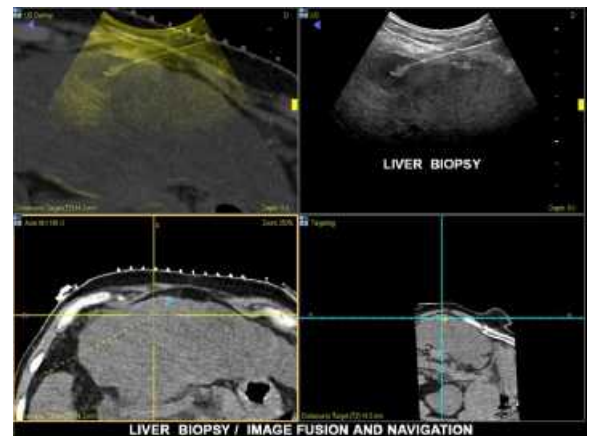
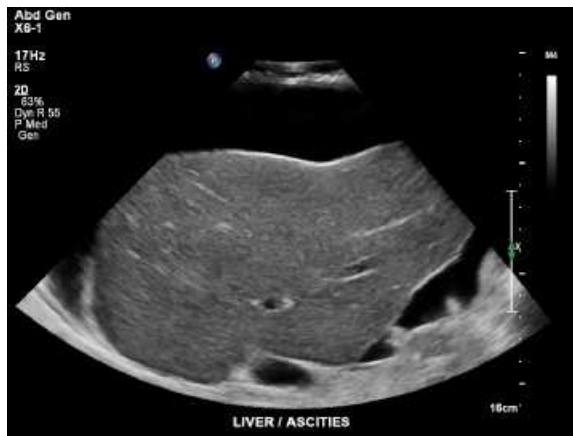
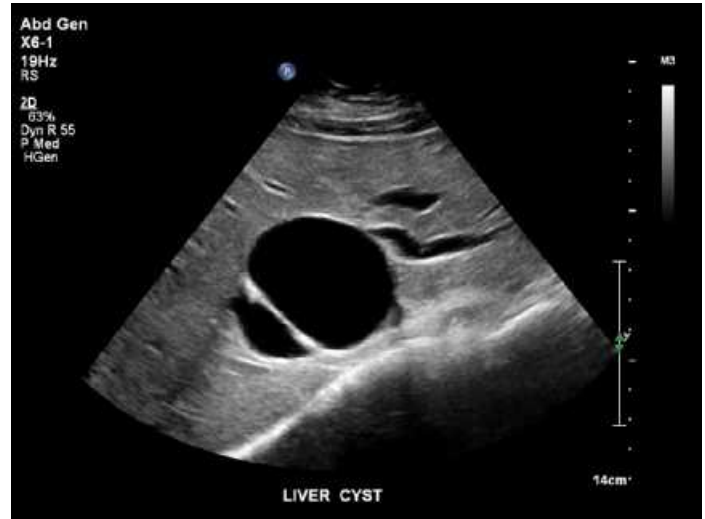
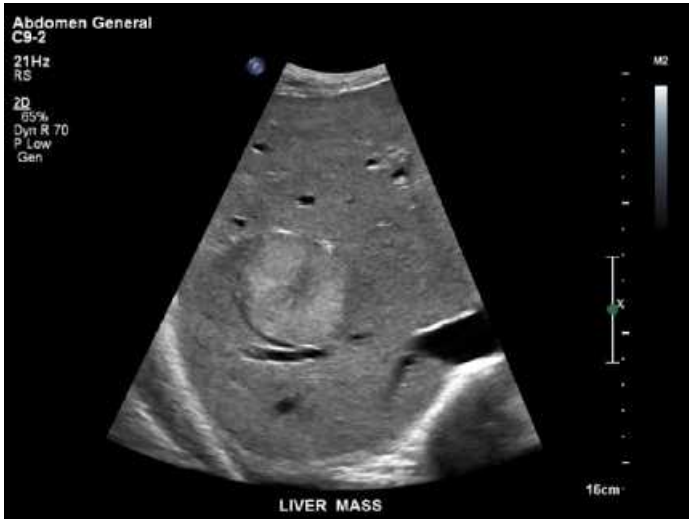Leveraging a more cost-effective approach

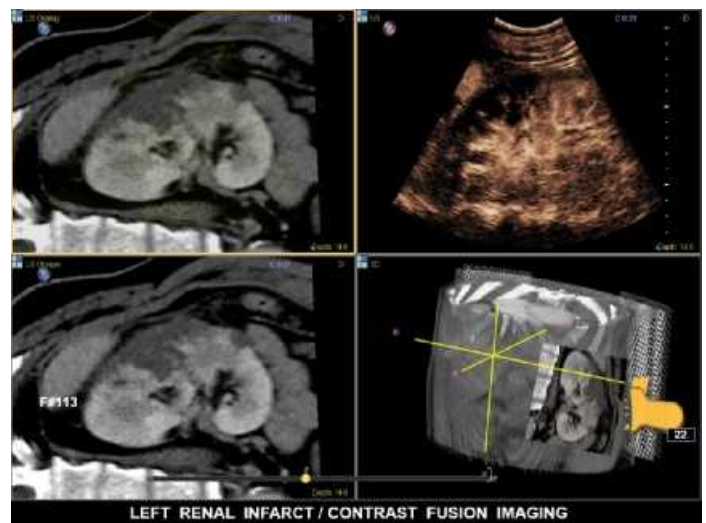
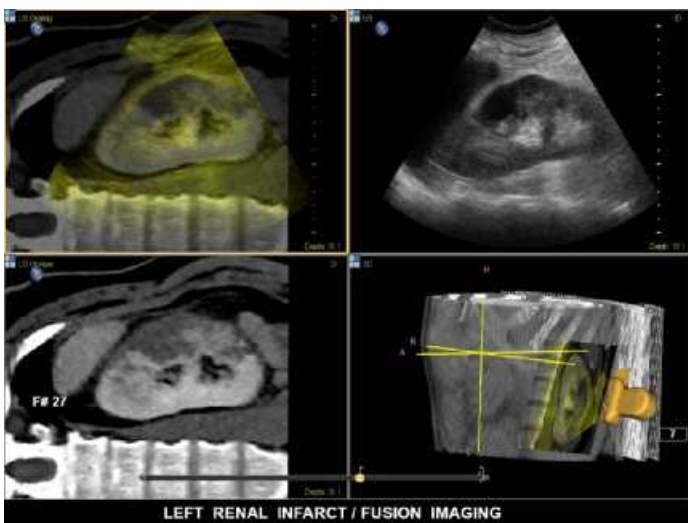
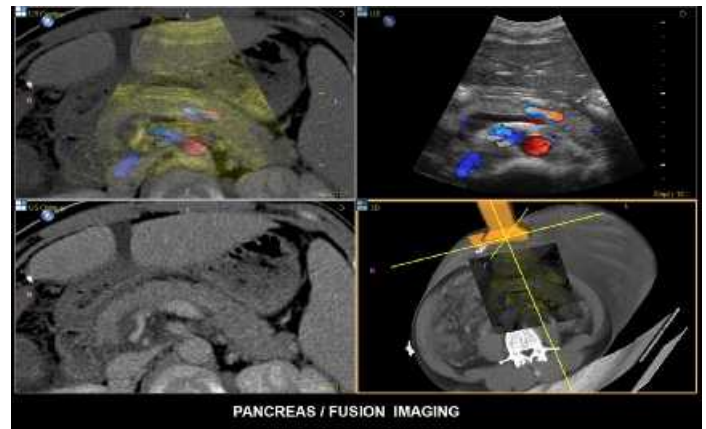
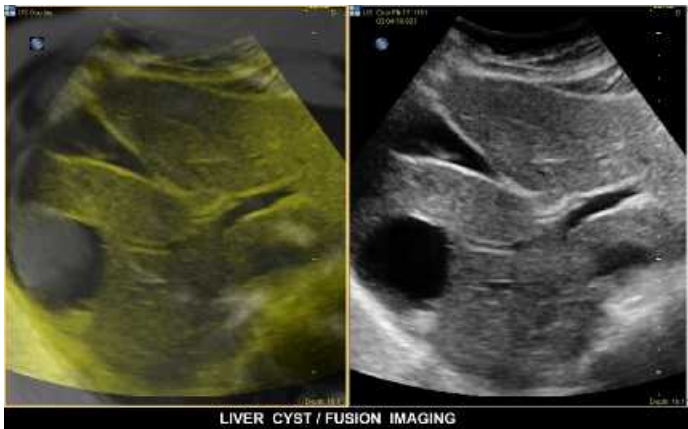
Dr. Clevert sees benefits to more judiciously evaluating the need for MR and CT exams. “Think of the money expended, for example, on a repeat MR--both on the exam and on the specific contrast agent. Contrast-enhanced ultrasound is a very inexpensive examination, and the agents are also inexpensive and without the same risk of nephrotoxicity. You can use resources more efficiently and free up the MR and CT scanners for other types of examinations,” he comments.



Benefits of fusion imaging using ultrasound

- Advanced visualization for enhanced diagnostic confidence
- Direct comparison of lesions through multiple modalities
- More precise monitoring of lesion progression
- Reduced radiation exposure
- More efficient use of resources





nSIGHT Imaging is a totally new approach

The Philips proprietary **nSIGHT** Imaging architecture, featured in the EPIQ 7 ultrasound system, introduces a totally new approach to forming ultrasound images without compromise. Unlike conventional systems that form the image line by line, **nSIGHT** creates images with optimal resolution down to the pixel level.

Proprietary **nSIGHT** Imaging incorporates the use of a new precision beamformer along with powerful massive parallel processing. This extraordinary architecture captures an enormous amount of acoustic data and then reconstructs in real time optimally focused beams, creating precise resolution for every pixel in the image.

For the first time, users can experience both highly detailed ultrasound images and extraordinary temporal resolution and frame rate through virtually perfect beams with fewer transmit operations, breaking the traditional compromise of conventional architectures.

nSIGHT offers superb tissue uniformity all the way up to the skin line without the compromise of conventional transmit focus limitations through dynamic calculation and reconstruction of optimal transmit and receive focusing continually at all depths down to the pixel level.

Looking ahead

“I think the demand for this option will continue to grow,” Dr. Clevert says. “I believe this examination will be done as a starting point for difficult cases in the future. Radiologists are the most likely users because they have experience on how to interpret MR or CT exams, and they can use current exams or access previous MR or CT data from the PACS system.”

“When you combine the advantages of all the other modalities with ultrasound, at the end of the day it makes a better diagnosis for the patient.”

Dirk-André Clevert, MD

Changing the course of treatment

Dr. Clevert provides an additional example of the difference that combining modalities to guide treatment can have, recounting, “Last week a patient was sent to me for a pre-surgical evaluation of a tiny lesion of about 1.5 cm diameter on the kidney. The patient was scheduled for renal surgery because the CT examination suggested it was renal cell cancer.”

“Due to the fact that we have a very close working relationship with our urology department, one of my colleagues sent this patient to me to try to determine if it

was actually renal cell cancer or perhaps another type of cyst. I used the data, and looked at both contrast-enhanced ultrasound and CT,” he explained.

“Did we see any ultrasound contrast uptake? No, and so it was not a cancerous lesion. This changed the course of treatment – surgery was not indicated and the patient was cleared from surgery, which had been scheduled for the next day. When we can rule out or confirm cancer it has a major impact on the patient.”

Please visit www.philips.com/EPIQ



© 2013 Koninklijke Philips N.V.
All rights are reserved.

Philips Healthcare reserves the right to make changes in specifications and/or to discontinue any product at any time without notice or obligation and will not be liable for any consequences resulting from the use of this publication.

Philips Healthcare is part of Royal Philips

www.philips.com/healthcare
healthcare@philips.com

Printed in The Netherlands
4522 962 94411 * SEP 2013